

Detection of sizeable Infarcted Scarred Myocardium in Symptomatic Post Revascularisation patients using Gated Spect Myocardial Perfusion Scintigraphy.



Mahapatra G.N.*,
Halkatti P.C.,** Dixit M.D.,***
Harshvardhan K.H.*

*Department of Nuclear Medicine,

**Cardiology and

***Cardiothoracic surgery.

KLES Hospital and Medical
Research Centre, Belgaum,
Karnataka.

mahptrag@bom5.vsnl.net.in

Gated SPECT myocardial perfusion scintigraphy is described as an accepted non invasive modality of investigation in patient having know history of old myocardial infarction with documented significant coronary occlusion in single and multiple vessel involvements for the amount of viable myocardium before subjecting them to revascularisation. It has been a mandatory protocol which should be strictly followed in every known CAD patient prior to myocardial revascularisation. We report the case of symptomatic 54 year old male of post CABG done few years back with multiple moderate areas of fixed perfusion defects amounting to sizeable infarcted myocardium with dilated LV cavity with low LVGEF at rest with further deterioration in LV function at stress.

Keywords:

Gated SPECT myocardial perfusion scintigraphy , LVGEF (Left ventricular global ejection fraction), stress perfusion defects, gross hypokinesia to akinesia (absence movement of the infarcted myocardial segment), systolic wall thickening (further inceases in the myocardial activity during systole).

Case Report:

A 54 year old symptomatic business man presented to the cardiac clinic for an intermittent angina. He is a known case of old infero lateral MI with post CABG-LIME done to proximal and mid LAD and SVG graft to OM3 4-5 years back at Pune. Routine ECG shows prominent 'q' wave in V5, V6, II, III, aVF, 2D echocardiography

reveals normal resting LV function with concentric LVH with gross hypokinesia to akinesia involving inferior and postero lateral segments. Gated stress and rest Tc99m tetrofosmin myocardial perfusion scan was performed under SPECT gamma camera interfaced with computer on a treadmill exercise table. The various stress and rest slices generated from the computer reveals dilated LV cavity with subnormal LVGEF at rest (43%) with significant fall in LVGEF at stress (39%) with multiple moderate areas of fixed perfusion defects involving inferior and posterolateral segment of myocardium with akinetic segment without any significant systolic wall thickening either at stress and rest imaging suggestive of the presence of sizeable infarcted scarred myocardium inspite of SVG graft to OM1 and OM3 in CABG surgery.

Discussion:

Utility of gated SPECT Tc-99m tetrofosmin myocardial perfusion scinitigraphy in detecting infarcted myocardium is well documented and it is a mandatory investigation to be performed routinely before CABG surgery. Unfortunately in this patient, myocardial perfusion scan was not undertaken to assess the myocardial viability before CABG surgery. However LIMA graft to LAD artery is patent showing uniform stress perfusion pattern involving antero septal segment.

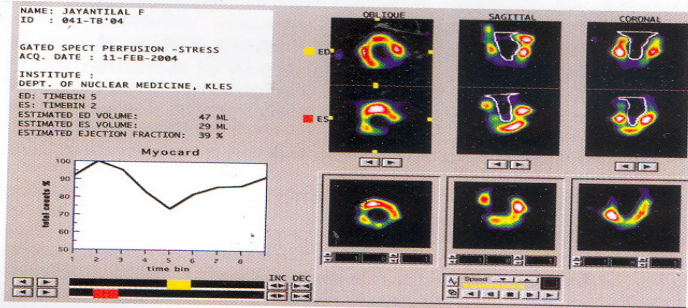


Fig1. Stress gated tetrofosmin perfusion study reveals no further rise in global ejection fraction with no evidence systolic wall thickening.

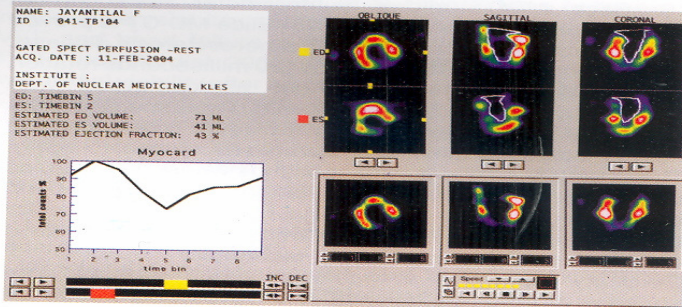


Fig2. Resting Gated tetrofosmin study showing subnormal global ejection fraction without any evidence of systolic wall thickening.

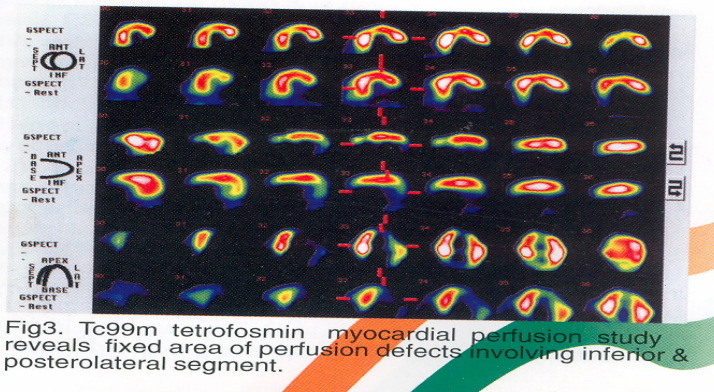


Fig3. Tc99m tetrofosmin myocardial perfusion study reveals fixed area of perfusion defects involving inferior & posterolateral segment.

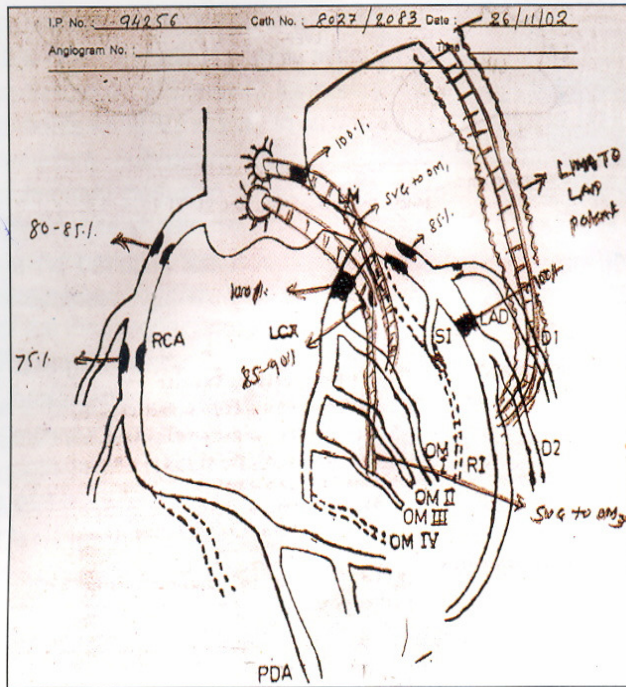


Fig4. Coronary Angiography reveals patent LIMA to LAD artery and SVG to OM3.

Conclusion:

Therefore we conclude from this present report that myocardial viability is a mandatory investigation before any type of revascularisation (CABG/angiography) is planned or else the patient would not be benefitted from the procedure.

Reference:

1. Pohost GM, Zir, LM, Moore RM, Mckusick KA, Guiney TE, Beller GA, Differentiation of transiently ischaemic from infarcted myocardium by serial imaging after single dose of Thallium-201. Circulation 1977;SS:294-302.
2. Tamaki N, Yonekura Y, Yamshita K, et al. SPECT Thallium-201 tomography and positron tomography using N-13-Ammonia and F-18-fluorodeoxyglucose in coronary artery disease. Am Cardiac 1989;3;3-9.
3. Bruken Rc, Kottou S, Nienaber CA, et al. PET detection of viable tissue in myocardial segment with persistent defects at TI-201 SPECT. Radiology 1989;172:65-73.
4. Gutman J, Berman DS, freeman M, et al. Time to complete redistribution of Thallium-201 in exercise myocardial scinitigraphy, relationship to the degree of coronary artery stenosis. Am Heart J, 1983;106;989-995.

5. Kiat H, Berman DS, Maddahi J, et al. Late reversibility of tomographic myocardial Thallium-201 defects an accurate, JACC 1988;12;99545-9963.
6. Rocco T, Dilsizian V, Maltais F, Strauss HW, Boucher CA, Mckusick KA. Thallium-201 reinjection after delayed imaging demonstrates fill-in to regions with "fixed" defects (abstract). J Nuclear Medicine 1998;29:769.